



Critical View of Safety during Laparoscopic Cholecystectomy

Raad Saad Al Saffar* and Haider Abdul Zahraa J. Al Khaqany Al Khaqany

Al Sader Teaching hospital, Al Najaf Al Ashraf, Iraq

**Corresponding author*

Abstract

Cholecystectomy is the most common surgical procedure done laparoscopically worldwide. Many techniques and approaches are used like (infundibular technique, fundus first, partial or subtotal cholecystectomy), However the critical view of safety (CVS) technique is a safe option and appears to minimize bile duct injury. We tried to determine the safety of this technique in patients managed with laparoscopic cholecystectomy (LC). Hence, a prospective study was carried on during 4 years; 2012-2016 and a total of 500 patients with gallstone diseases managed with laparoscopic cholecystectomy at Al Sader Medical city in Al Najaf Al Ashraf governorate. The mean age of the patients was 42.5 (range: 20-65) years. Our patients were 382 Females and 118 males. All LCs were completed successfully with no conversion. Total operating time ranged from 40-70 minutes. No mortalities occurred in the study, CBD injury in only one patient. In conclusion, the Critical View of Safety technique is a safe option and recommended to be the gold standard technique in the laparoscopic cholecystectomy.

Article Info

Accepted: 02 July 2017
Available Online: 20 July 2017

Keywords

*Laparoscopic cholecystectomy,
Worldwide,
Critical view*

Introduction

The Traditional open cholecystectomy performed for the first time in 1882 by Carl August Langerbach he appropriately stated “The gallbladder needs to be removed not because it contains stones, but because it forms them”, has been replaced by laparoscopic cholecystectomy, first performed by Muhe in 1985 which has revolutionized the treatment of gallbladder disease and is now the gold standard for the treatment of gallstones and the commonest operation performed laparoscopically worldwide.¹

Strasberg *et al.*, (2010) in the early nineties, pointed out how a “critical view of safety” (CVS) should be achieved every time, by dissecting the entire infundibulum off the liver bed and by freeing it of all fatty tissue, both in its

dorsal and ventral aspects. This, in his opinion, would have prevented accidental biliary and vascular injuries, due to uncommon variations, incautious bleeding control, or unclear anatomy.

These principles have been ignored until recent years, when standardization of the technique, together with some consistent data, have appeared in the literature, asserting that this way of dissecting the gallbladder pedicle would bear a highly protective role against bile duct injuries. This would be especially important in teaching the approach to the gallbladder hilus.²

When surgeon faces an unusual or distorted anatomy, limited knowledge of the Calot’s triangle dissection techniques is not only insufficient but also unsafe from a surgical perspective. This potentially could lead to the

considerable difficulties at operation and an increased risk of biliary tree injury.³

Serious complications that occur with laparoscopic cholecystectomy, including bile duct injury, bile leaks, bleeding and bowel injury result in part from patient selection, surgical inexperience, and the technical constraints that are inherent to the minimally invasive approach.⁴

A major mode of ductal injury is diathermy burns, which may initially go unnoticed and usually involve the right or common hepatic ducts. These factors, as well as intrinsic sequelae of biliary tract diseases, such as inflammation and scarring, have led to the concept of "Stop Rules" for surgeons performing this operation. In essence, if a safe dissection cannot be ensured laparoscopically, early conversion to an open approach should be readily accepted as the proper course.^{5,6}

The "critical view of safety" (CVS) technique recommends clearing the triangle of Calot of fat and fibrous tissue and taking the gallbladder off the lowest part of its attachment to the gallbladder bed. CVS clarifies the relations of the anatomic structures that should be divided, and therefore, it should be ideally and routinely applied in all LCs because of its highly protective role against bile duct injuries. Laparoscopic subtotal cholecystectomy is a safe and feasible alternative to conversion to open surgery during difficult laparoscopic cholecystectomy for patients with complicated cholecystitis.⁷

Patients and Methods

From October 2012 to October 2016 a prospective study involving five hundred (500) patients with gallbladder disease underwent laparoscopic cholecystectomy (LC) in Al Sader Medical city in Al Najaf Al Ashraf governorate by one surgeon (Consultant Surgeon *Dr Raad S. Al Saffar*) and his team.

Inclusion criteria

Patients of either sex, more than 13 years of age who underwent laparoscopic cholecystectomy were included in the study.

Exclusion criteria

The patients who had jaundice, mass or dilated common bile duct CBD > 10 mm in diameter a hepatitis B or C positive patients were excluded.

The laparoscopic cholecystectomy was done by using a laparoscope (Storz) with standard 3 ports technique with few modifications depending upon the situation such as an additional port.

The first port is a 10 mm infraumbilical camera port inserted after achieving pneumoperitoneum by using of veress needle for CO₂ insufflation and the other two ports are inserted under direct camera vision.

In some situations (like previous scar or presence of anterior abdominal wall hernias) we avoided umbilicus as the initial site of veress needle insertion. We chose a safe site for the creation of pneumoperitoneum, we used the proposed epigastric port, slightly above transpyloric plane in the midline. We felt comfortable doing it in the left hypochondrium 2 cm below the subcostal margin in the midclavicular line (Palmer Maneuver).

Rouvier's sulcus (RS) (i.e. incisurahepatisdextra, Gansincisura) represented an important extrabiliary anatomical landmark, it was found in most of cases.

Three criteria were required to achieve the CVS

1. The hepatocystic triangle is cleared of fat and fibrous tissue. The hepatocystic triangle is defined as the triangle formed by the cystic duct, the common hepatic duct, and inferior edge of the liver. The common bile duct and common hepatic duct do not have to be exposed.
2. The lower one third of the gallbladder is separated from the liver to expose the cystic plate. The cystic plate is also known as liver bed of the gallbladder and lies in the gallbladder fossa.
3. Two and only two structures should be seen entering the gallbladder.

Finally both cystic artery and duct are double clipped separately by using hemo-lock clips for the duct and Ackermann titanium clips for the artery (Figure1)

Results and Discussion

Five hundred LC were performed for gallstone disease, the age ranged from 20 years to 65 with a mean of 42.5 years.

There were 382 females and 118 males in the study population with male to female ratio 1:3.2 (Figure 2). All

the 500 (100%) LCc were completed successfully without need for conversion Total operating time ranged from 40-70 min with a mean of 55 min, maximum patients (90%) were operated between 40-50 min. Fortunately, no mortalities occurred in the study, morbidity was (0.2 %), CBD injury was occurred in only patient and diagnosed post operatively by jaundice and persistent bile leak, then re-explored without ERCP and type D Strasberg injury was found, the patient did well and discharged 5 days post operatively. Another 11 patients (2.2%) had bile leak, all are managed conservatively, 28 (5.6 %) patients underwent partial or subtotal cholecystectomy due to adhesions and obscured anatomy in the Calot Triangle.³⁵ Seven percent patients found to have empyema of the gallbladder and successfully operated on laparoscopically. Majority of the patients 488 (97.6 %) discharged well after 24-48 hours, only 12 (2.4 %) patients need longer duration of hospital stay, 4-10 days, due to postoperative complications mentioned in (Table 1).

Bile duct injuries during laparoscopic cholecystectomy remain an important cause of morbidity, mortality, increased hospital stay, and litigation. Yegiyants and Collins (2008) reported that: their rate varies from 0.3% to 0.5% and has not changed considerably since the introduction of laparoscopic surgery in early 1990, this is higher than reported in our study which is 0.2% only. This is mostly related to the surgeon skills and awareness while dissecting near calot especially when critical view of safety applied.⁸

In 2009 Avgerinos *et al.*, showed there was no bile duct injury in the 1,046 cholecystectomies. Postoperatively, five patients had bile leaks which were transient and stopped spontaneously after 2–14 days. Two reoperations

were performed because of severe bleeding. However they reported that 27 patients needed conversion to the open approach (2.6%), while there was no conversion in all of the 500 patients we operated on (i.e. 0%) conversion rate.⁹

The most advantage of identifying Rouvier’s Sulcus (RS) lies in the fact that the cystic duct and the cystic artery lay anterosuperior to the sulcus and the common bile duct lies below the level of RS. Hugh (2002) had shown minimal bile duct injury during laparoscopic cholecystectomy by beginning the dissection ventral to the RS.¹⁰

We agreed Strasberg *et al.*, (2010) when suggested that no clipping or cutting should be done until the Calot's triangle is cleared from all fat to visualize only two structures: the cystic artery and duct.²

However we feel better to be patient before applying the concept of "Stop Rules" advised by Strasberg *et al.*, (2005) for surgeons performing LC. In essence, if a safe dissection cannot be ensured laparoscopically, early conversion to an open approach should be readily accepted as the proper course.⁵

Instead Laparoscopic subtotal or partial cholecystectomy was used for difficult gallbladder bed, difficult hilum, or both and it is feasible and safe option in difficult situations during performing standard Laparoscopic cholecystectomy in regards to conversion rate, post-operative morbidity and complications, duration of post-operative hospital stay, resumption of diet, operation time, perioperative blood loss in all age groups and gender this is agreed by Dilip *et al.*, (2014).¹¹

Table.1 Post-operative complications in patients underwent LC

Complication	Number of patients	%
Bile Leak	12	2.4
Port site infection	18	3.6
Jaundice	6	1.2
Chest infection	5	1.0
Intra-abdominal collection	8	1.6

Fig.1 Critical View of Safety (anterior and posterior)

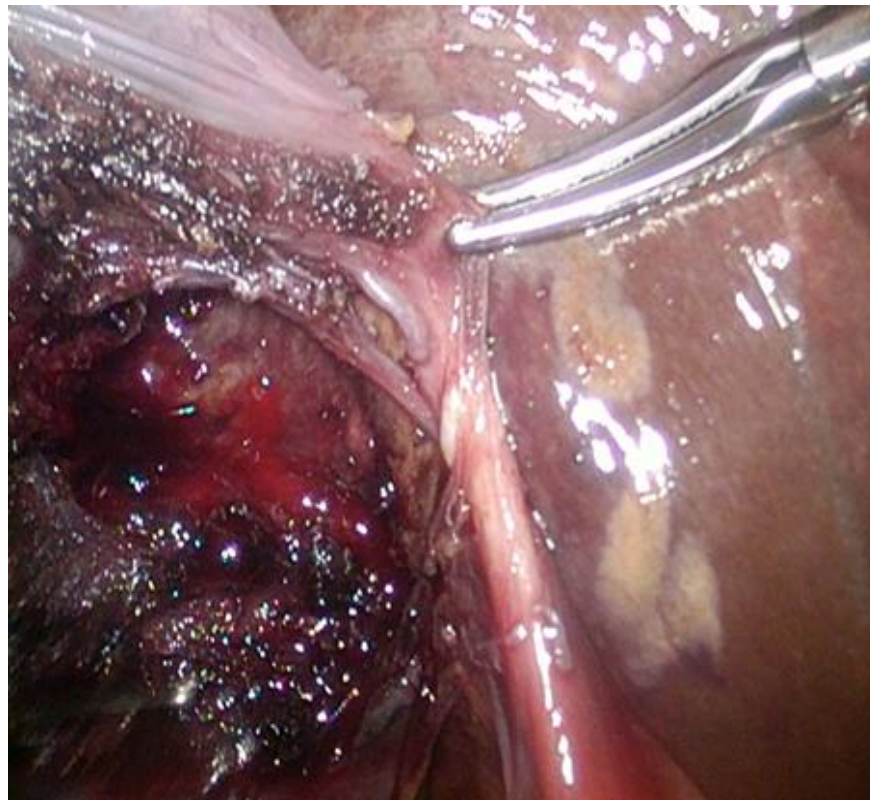
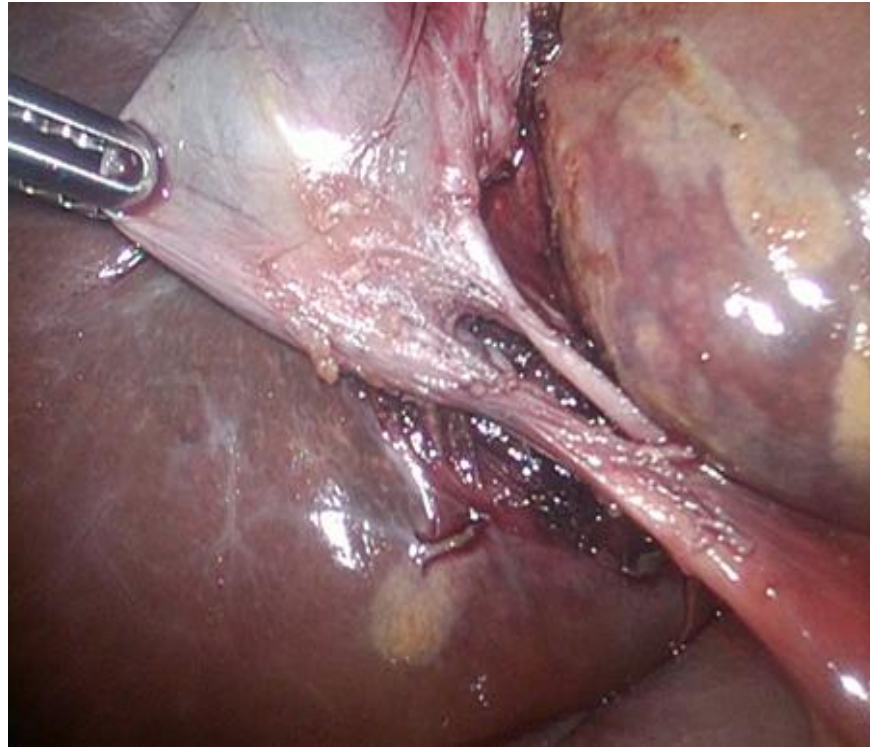
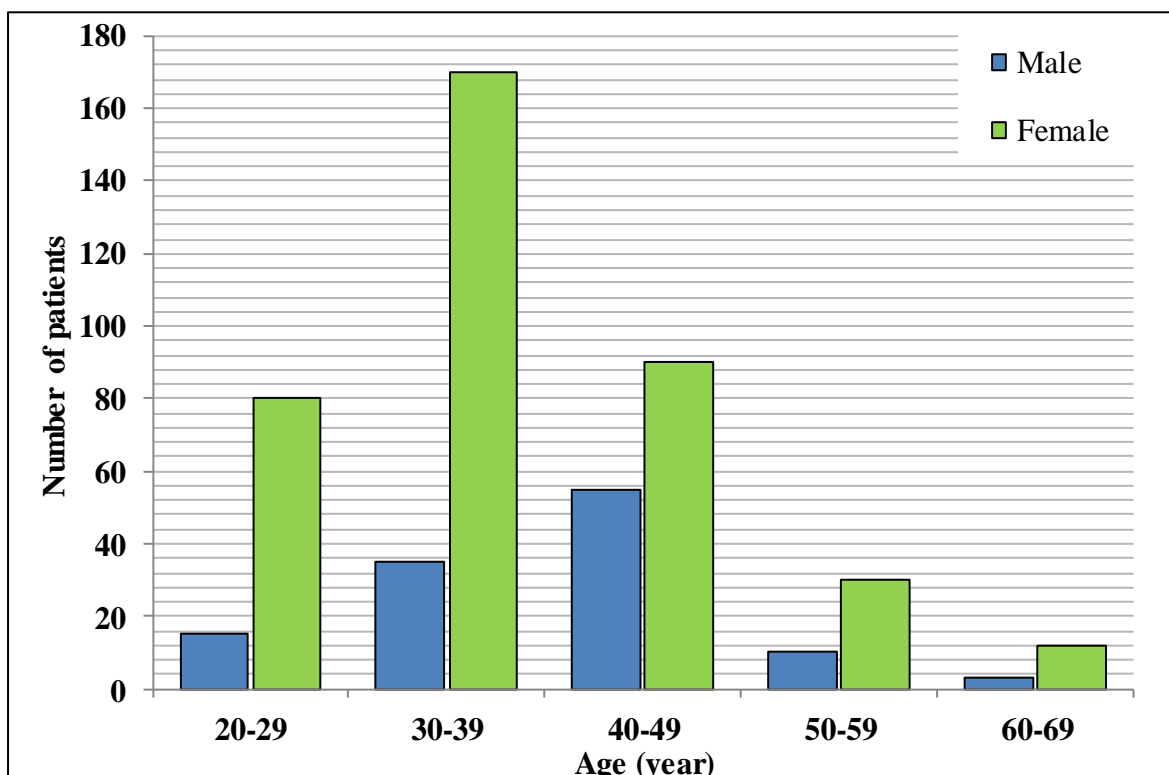


Fig.2 Age and Sex distribution of the 500 patients managed with LC



As presented in the July 2010 issue of Journal of the American College of Surgeons by Drs Strasberg and Brunt, 1 attaining the critical view of safety (CVS) so that the gallbladder is hanging from the cystic duct and artery is surely protective against misidentification of the common bile duct as the cystic duct, which is the most common cause of serious bile duct injury associated with laparoscopic cholecystectomy. The achievement of CVS requires complete dissection of the fat and fibrous tissue in the triangle of Calot, which can be performed even by trainees when the triangle is not inflamed or is mildly inflamed. 3

We felt comfortable to start our dissection posteriorly above the level of Rouvier's Sulcus which represented a reliable land mark then to proceed anteriorly exposing the cystic plate, however this against Almutairi et al., (2009), they thought that the cystic artery proper and its terminal branches are constant and form a reliable land mark for the initiation of our dissection. Moreover, following the cystic artery branches from the gallbladder wall will clarify if there is a posterior branch which can be preserved to be dissected after the triangle of safety technique (T ST) view is established. 12

The post-operative complications managed conservatively in a period didn't exceed 10 days in most cases, No major bile leaks encountered all of eleven cases were minimal leaks that stopped in a period not more than 10 days, this is same to Kumar *et al.*, (2007), only one patient with CBD injury re explored in same admission (4th post-operative day). However most of our patients had a smooth postoperative course and discharged well from the hospital after 24 -48 hours.

References

- Almutairi AF, Hussain YAMS. Triangle of safety technique: a new approach to laparoscopic cholecystectomy. *HPB Surg.* 2009; ID476159: 1–5.
- Avgerinos C, Kelgiorgi D, Touloumis Z, Baltazi L, Dervenis C. One thousand laparoscopic cholecystectomies in a single surgical unit using the “critical view of safety” Technique. *J Gastrointest Surg* 2009; 13:498–503.
- DilipGode, C Palanivelu, Zahiruddin Quazi Syed / new variants of laparoscopic subtotal cholecystectomy in management of acute cholecystitis. JN medical college, Datta Meghe Institute of medical sciences, Wardha, Maharashtra, India 2014.

- Friedman G.D. Natural history of symptomatic and asymptomatic gallstone. *Am J Surg.*, 1993; 165:399.
- Hugh T. B., New strategies to prevent laparoscopic bile duct injury-surgeons can learn from pilots. *Surgery*, vol. 132, no.5, pp. 826-835, 2002.
- Khan MH, Howard TJ, Fogel EL, et al., Frequency of biliary complications after laparoscopic cholecystectomy detected by ERCP: experience at a large tertiary referral center. *Gastrointest Endosc* 2007; 65:247.
- Kumar S et al., Laparoscopic Cholecystectomy: An experience at Liaquat University Hospital, Jamshoro, Pakistan 2007.
- Strasberg SM, Brunt LM. Rationale and use of the critical view of safety in laparoscopic cholecystectomy. *J Am Coll Surg.* 2010 Jul; 211(1):132–138.
- Strasberg SM, Hertl M, Soper NJ. An analysis of the problem of biliary injury during laparoscopic cholecystectomy. *J Am Coll Surg.* 1995; 180: 101–125.
- Strasberg SM. Biliary injury in laparoscopic surgery: part 1. Processes used in determination of standard of care in misidentification injuries. *J Am CollSurg* 2005; 201:598.
- Strasberg SM. Biliary injury in laparoscopic surgery: part 2. Changing the culture of cholecystectomy. *J Am CollSurg* 2005; 201:604.
- Tian, Y., Wu, S.D., Su, Y., Kong, J., Yu, H. and Fan, Y. (2009) Laparoscopic Subtotal Cholecystectomy as an Alternative Procedure Designed to Prevent Bile Duct Injury: Experience of a Hospital in Northern China. *Surgery Today*, 39,510-513.
- Yegiyants S, Collins JC. Operative strategy can reduce the incidence of major bile duct injury in laparoscopic cholecystectomy. *Am Surg.* 2008 Oct; 74(10): 985–987.

How to cite this article:

Raad Saad Al Saffar and Haider Abdul Zahraa J. Al Khaqany Al Khaqany. 2017. Critical View of Safety during Laparoscopic Cholecystectomy. *Int.J.Curr.Res.Aca.Rev.* 5(7), 70-75.

doi: <https://doi.org/10.20546/ijcrar.2017.507.010>