



International Journal of Current Research and Academic Review

ISSN: 2347-3215 Volume 3 Number 2 (February-2015) pp. 71-74

www.ijcrar.com



Fused ribs- A case report

Sunkeswari Sreepadma*, Chaithra Rao B.R., Nandini B.N., Veena Kulkarni and
Rajeev Joshi

Department of Anatomy, SDM Medical College, Dharwad, Karnataka, India

*Corresponding author

KEYWORDS

Fused ribs,
Skeleton,
Thoracic
insufficiency
syndrome

A B S T R A C T

The abnormalities in the thoracic rib cage may be an indication for few systemic disorders. The fusion of ribs is a rare condition which may result in thoracic deformity, restricted lung growth. The knowledge of such rare variation is important for appropriate diagnosis.

Introduction

The ribs are 12 pair of elastic arches. They articulate posteriorly with the vertebral column and form greater part of the thoracic skeleton. Their number may be increased by cervical or lumbar ribs or reduced by the absence of the twelfth pair. The first seven pairs of ribs are connected to the sternum by costal cartilages, and are referred as true ribs. The remaining five are called false ribs. The ribs are separated by intercostals spaces, which are deeper in front and between the upper ribs. The latter are less oblique than the lower ribs; obliquity is maximal at the ninth rib and decreases to the twelfth (Gray, 1989). In few cases, the ribs fuse and are associated with progressive scoliosis, thereby reducing the thoracic volume. Fused ribs are also encountered in Gorlin's syndrome (Glass et al., 2002). The costal anomalies occur quite frequently at the

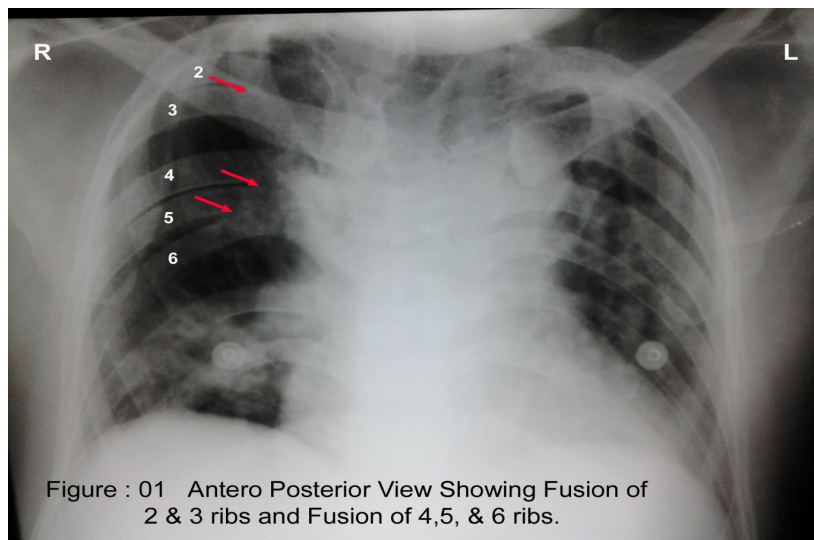
thoracic outlet, presence of cervical rib and hypertrophied scalenus anterior muscle have been regarded as important factors in the genesis of thoracic outlet syndrome (White et al., 1945; Baumgartner et al., 1989). The rib anomalies whether pathological or normal variants such as cervical rib, pelvic rib, bifid rib, bicipital ribs etc., often indicate an underlying systemic disorder. The present case report is an attempt to highlight the clinical significance of the fused ribs.

Case report: A 40 yr old male presented with acute onset of breathlessness. Routine examination was done. Chest radiograph showed fusion of 2nd and 3rd ribs and also fused 4th, 5th and 6th ribs posteriorly (Fig. 1). The fusion of ribs was seen only on right side and left side thoracic cage appeared normal. Investigations revealed reduced

lung volume, raised total count, arterial blood gases showed reduced PaO₂ and normal PaCO₂. ECG showed changes of ischaemia. Echo reported decrease in cardiac function.

Discussion: Abnormalities detected in the ribs can sometimes be the initial indication of systemic disease. Rib changes can indicate generalized bone dysplasias, metabolic diseases, and trauma. Extensive thoracic congenital scoliosis associated with fused ribs may affect thoracic function and growth and have an adverse effect on the function and growth of the lungs (Campbell et al., 2003). This condition can be referred to as thoracic insufficiency syndrome, which is defined as the inability of the thorax to support normal respiration or lung growth. Anatomically, the actual portions of the chest wall involved in the rib fusion can be considered areas of segmental hypoplasia of the hemithorax. The term jumbled spine has been used to describe extensive congenital scoliosis (McMaster, 1994). Lung growth is limited to the anatomic boundaries of the thorax, so any spine or rib cage malformation that reduces the thoracic volume early in life may adversely affect the size of the lungs at skeletal maturity (Davies and Reid, 1971).

Patients with restrictive lung disease may tolerate it clinically for a long time, but after the age of forty years some will become dependent on oxygen or ventilator support, with a marked increase in the mortality rate with aging (Pehrsson et al., 1991). When a thorax with fused ribs cannot support normal respiration through secondary breathing, the child, may compensate with an increased respiratory rate, mediated through the diaphragm, and may decrease activity in order to maintain adequate levels of arterial oxygen. This compensation mechanism may enable a child to appear clinically normal, even when he or she has mild thoracic insufficiency syndrome. Progression of the thoracic deformity causes progressive thoracic insufficiency syndrome with further loss of chest wall motion and thoracic volume. The underlying lungs may be compressed with development of atelectasis (essentially areas of nonfunctioning lung), and expansion of the lungs for respiration becomes totally dependent on the function of the diaphragm. Eventually the child may be unable to compensate and clinical respiratory insufficiency will occur, first with the development of dyspnea and then with the need for supplemental oxygen or even ventilator support to maintain arterial oxygen levels for survival.



Fused ribs are also encountered in Gorlin syndrome. Rib resection and deformity that result from thoracotomy are asymptomatic. However, rib fusion will cause scoliosis and restriction of chest wall expansion, which may require surgical intervention (Glass et al., 2002). Fusion of ribs occasionally occurs posteriorly when two or more ribs arise from a single vertebra. Fused ribs are often associated with a hemivertebra. In normal circumstances, the developing vertebral bodies have two chondrification centres that soon unite (Keith and Moore, 2008). A hemivertebra results from failure of one of the chondrification centres to appear and subsequent failure of half of the vertebra to form. These vertebral defects produce scoliosis of the vertebral column.

Conclusion

Many skeletal abnormalities accidentally detected during routine examinations should be further evaluated to detect the underlying systemic diseases. Evaluation of ribs in patients with neoplasms and congenital bone dysplasias can reveal valuable diagnostic details.

References

- Baumgartner, F., Nelson, R.J., Robertson, J.M. 1989. The rudimentary first rib: A cause of thoracic outlet syndrome with arterial compromise. *Arch. Surg.*, 124: 1090–1092.
- Campbell, R.M., Smith, M.D., Mayes, C.T., Mangos, A.J., Willey-Courand, B.D., Kose, N., Pinero, F.R., Alder, E.M., et al. 2003. The characteristics of thoracic insufficiency syndrome associated with fused ribs and congenital scoliosis. *JBJS*, 85-A(3): 399–408.
- Davies, G., Reid, L. 1971. Effect of scoliosis on growth of alveoli and pulmonary arteries and on the right ventricle. *Arch. Dis. Child.*, 46: 623–32.
- Glass, R.B., Norton, K.I., Mitre, S.A., Kang, E. 2002. Pediatric ribs: a spectrum of abnormalities. *Radiographics*, 22: 87–104.
- Gray, H. 1989. Williams, P.L. (Ed.), Gray's anatomy, 37th edn. C. Livingstone, Edinburgh.
- Keith, L., Moore, 2008. The developing human: clinically oriented embryology, 8th edn. Saunders, Philadelphia, PA. Pp. 351.
- McMaster, M.J. 1994. Congenital scoliosis. In: Weinstein, S.L. (Ed.), The pediatric spine: principles and practice. Raven Press, New York.
- Pehrsson, K., Bake, B., Larsson, S., Nachemson, A. 1991. Lung function in adult idiopathic scoliosis: a 20 year follows up. *Thorax*, 46: 474–8.
- White, J.C., Poppel, M.H., Adams, R. 1945. Congenital malformations of the first thoracic rib: A cause of brachial neuralgia which simulates the cervical rib syndrome. *Surg. Gynecol. Obstet.*, 81: 643–659.