



doi: <https://doi.org/10.20546/ijcrar.2021.905.001>

## Unicycstic Ameloblastoma Crossing Midline of Mandible : An Unusual Case Report

Lalit Gade<sup>1</sup>, Sachin Kandalkar<sup>2\*</sup>, Ketan Saraf<sup>1</sup>, Mahesh Gadakh<sup>2</sup> and Sachin Kandalkar<sup>2</sup>

<sup>1</sup>Department of Oral pathology, SMBT Dental college and PG research institute, Sangamner, Dist- Ahmednagar, Maharashtra, India

<sup>2</sup>Department of Oral pathology, SMBT Institute of Dental Sciences and Research, Dhamangaon, Nandi-Hills, Nashik, Maharashtra, India

\*Corresponding author

### Abstract

Ameloblastoma is benign odontogenic tumor having potential to grow into various size with tendency to recur. Unicycstic ameloblastoma is a less encountered variant among the all intraosseous variety of ameloblastoma. Radiographically it shows unilocular or multilocular radiolucency mainly in posterior mandible which is common in various odontogenic tumor and cysts, but radiolucency crossing the midline is extremely rare. Unicycstic ameloblastoma has less aggressive potential and recurrence may be seen after longer time, so long term follow up is essential in these cases. We are reporting case of unicycstic ameloblastoma in 45 year female involving mandible, crossing midline with unilocular radiolucency with radiopaque bony trabecule radiographically.

### Article Info

Accepted: 24 April 2021

Available Online: 20 May 2021

### Keywords

Ameloblastoma, Odontogenic tumor, Unicycstic ameloblastoma.

### Introduction

Many benign lesions cause mandibular swellings, and these can be divided into odontogenic and nonodontogenic origin. The most common tumor of odontogenic origin is ameloblastoma which develops from epithelial cellular elements and dental tissues in their various phases of development. More than 80% of all ameloblastomas are solid or multicystic variants, with unicycstic ameloblastoma being an important clinicopathologic form of ameloblastoma and occupying the remaining 20% of the cases along with peripheral ameloblastoma.[1] Unicycsticameloblastoma, a variant of ameloblastoma, was first described by Ackermann *et al.*, in 1988.[2] Unicycstic ameloblastoma (UCA) is the most common term used to designate its different pathological

entities. Sometimes these can present as a multilocular radiolucency which makes the use of the term —cystic ameloblastomal more appropriate.

However, some authors still believe that the notion that cystic ameloblastomas can have a —true clinical multicystic pattern is arguable and contend with the use of the term —unicysticameloblastoma.[3- 4]. The unicycstic ameloblastoma is a less encountered variant of the ameloblastoma, referring to those cystic lesions that show clinical and radiographic characteristics of an odontogenic cyst but in histologic examination show a typical ameloblastomatous epithelium lining part of the cyst cavity, with or without luminal and/or mural tumor proliferation. [4] This paper illustrates a case of unicycstic ameloblastoma of the mandible in an 45-year-old female.

## Case Report

A 45 year old female patient reported with the chief complain of swelling on right side of face since three months (Figure 1). Patient gave history of swelling in lower posterior region of jaw three years back and operated for the same. Past medical history was not contributory. Patient does not have any adverse habits. Patient was alright after the surgery for three years, and then she noticed the swelling on right side of face which gradually increased to present size.

There was no history of trauma, bleeding. Asymmetry of face was noticed on extraoral examination due to swelling on right side of face. Swelling was diffuse, smooth surfaced covered by normal skin, it was hard and painless on palpation. Intraorally swelling was seen in the right buccal vestibule. It was extended from 42 up to the 47 region obliterating buccal vestibule. It was 3X4 cm in diameter approximately. It was hard and non-tender on palpation. Missing 43, 44, 45, 46 were noticed.

OPG (Figure 2) showed radiolucent lesion with radiopaque bony trabeculae. It was extended from second molar of right side to lateral incisor on left side, through crossing the midline. Root resorption was seen with 31, 32, 41, 42. Missing 43, 44, 45, 46.

There was thinning of inferior border of mandible. CT scan (Figure 3) showed large expansile osteolytic lesion in right side of mandible crossing midline with thinning of the inferior border of mandible. There was destruction of the buccal cortical plate, which was seen in 3 D reconstruction view. On these findings it was provisionally diagnosed as ameloblastoma with odontogenic keratocyst and central giant cell granuloma considered in differential diagnosis.

On excisional biopsy, (Figure 4) gross specimen showed three to four bits of tissues with sizes ranging from 2X2 cm to 2 X1 cm, red to white in color with few extracted teeth with root resorption. There was no excessive bleeding during excision of the lesion.

Histologically, (Figure 5A) hematoxylin and eosin stained section under 10X showed cystic lumen lined by epithelium. Under 40X (Figure 5C) this lining was made up of hyperchromatic basal layer showing reverse polarity of nuclei, which was suggestive of ameloblastic epithelium. Overlying epithelial cells were loosely cohesive and resemble stellate reticulum. Section also showed (Figure 5B) ameloblastic epithelium growing in

the form of nodules in the connective tissue of cyst wall. On this, final diagnosis of unicystic ameloblastoma group III (mural) was confirmed.

## Results and Discussion

The WHO classified ameloblastoma into three variants such as conventional, Unicystic, and peripheral ameloblastoma, which differ in their relation to age, distribution, localization, imaging features and prognosis.[5]

Most ameloblastomas contain microcysts but the unicystic variant has a lining of flattened tumour cells which resemble those of non- neoplastic cysts, with nodular proliferation into the lumen without infiltration of tumour cells into the connective tissue wall.<sup>6</sup> The occurrence of unicystic ameloblastoma is between 5% to 22% of all types of ameloblastomas.<sup>8</sup> There is difference in the mean age according to the variants of unicystic ameloblastoma.

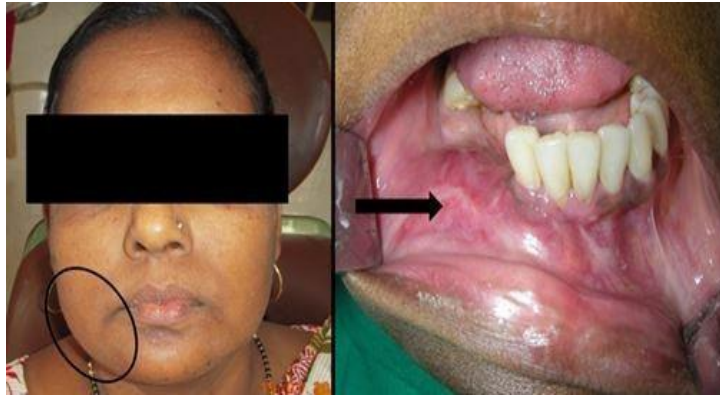The younger age group (10-20 years) in those cases diagnosed as dentigerous, as compared to nondentigerous seen in (40-70 years) old age group. In our case patient's age is 45 years going with the literature, with mandible is commonly involved as in our case also.<sup>1</sup> It occurs usually as asymptomatic, few cases may report with painless swelling of the jaws with facial asymmetry as in our case.[6]

Ackermann *et al.*, in 1988 classified this entity into the following three histologic groups: Group I—luminal Unicystic ameloblastoma (tumor confined to the luminal surface of the cyst); Group II- intraluminal/plexiform Unicystic ameloblastoma (nodular proliferation into the lumen without infiltration of tumor cells into the connective tissue wall); Group III—mural Unicystic ameloblastoma (invasive islands of ameloblastomatous epithelium in the connective tissue wall not involving the entire epithelium).

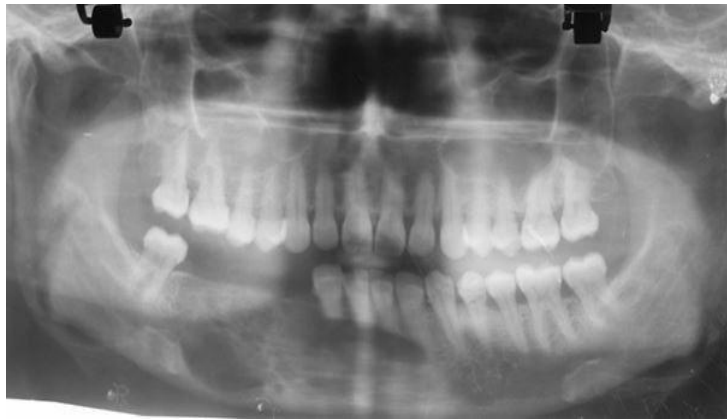Histologic subgrouping (modified after Ackermann *et al.*) by Philipsen and Reichart. Subgroup 1 - Luminal UA. Subgroup 1.2 - Luminal and intraluminal. Subgroup 1.2.3 - Luminal, intraluminal and intramural. Subgroup 1.3 - Luminal and intramural.[6]

Radiographic appearance or incisional biopsy cannot give diagnosis of unicystic ameloblastoma as incisional biopsy is not representative of the entire lesion, it may result in an incorrect classification.

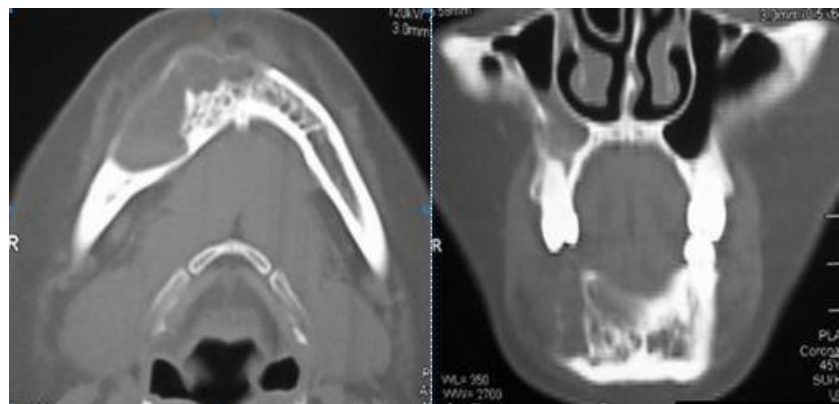
**Fig.1** Extraoral and intraoral swelling.



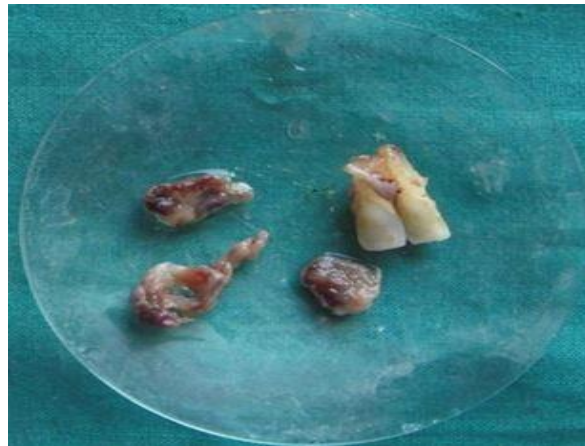**Fig.2** OPG radiolucent lesion crossing the midline with radiopaque bony trabeculae . Root resorption was seen with 31, 32, 41, 42.



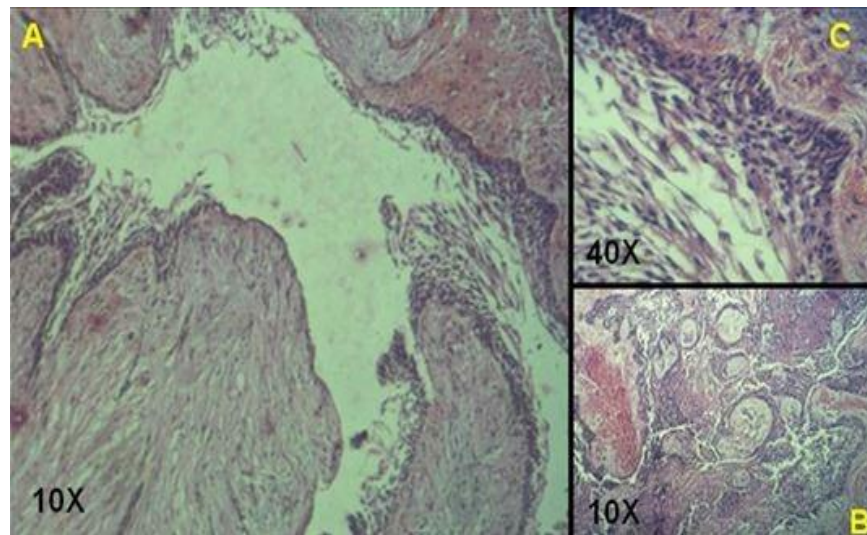
**Fig.3** CT showing large expansile osteolytic lesion of mandible crossing midline with thinning of the inferior border of mandible and destruction of the buccal cortical plate



**Fig.4** Gross specimen with cystic lining and teeth



**Fig.5** (Figure 5A) hematoxylin and eosin stained section showed cystic lumen lined by epithelium. (Figure 5B) ameloblastic epithelium growing in the form of nodules in the connective tissue of cyst wall under 10X. Under 40X (Figure 5C) lining shows hyperchromatic basal layer with reverse polarity of nuclei and overlying epithelial cells resemble stellate reticulum.



Multiple areas need to be evaluated to confirm that the tumor does not extend beyond the cyst wall.[8] In 1977 it is believed that unicystic ameloblastoma is less aggressive, and its response to enucleation or curettage is more favorable than the classic solid or multicystic ameloblastomas.[9]. Treatment recommended for ameloblastoma is usually wide resection as more recurrence is there, but it will cause masticatory dysfunction, facial deformity etc. so recurrence is not always considered fist but, morbidity and quality of life of patient should always be considered. The treatment for subgroups 1 and 1.2 may be enucleation, whereas for subgroups 1.2.3 and 1.3 it must be treated radically. [10]

Average interval of recurrence is 7 years. Recurrence rate according to type is 35.7% in those invading the fibrous wall while in others it is 6.7% only. According to treatment recurrence rate is less in resection i.e. 3.6% while in enucleation alone it is 30.5%, for enucleation followed by Carnoy's solution application 16%, and 18% by marsupialization followed by enucleation or resection. Though in unicystic ameloblastoma is less aggressive, treatment differ according to subtypes, so incisional biopsy not always helpful to plan the treatment as it represent only small area. Finally this is rarest case where within small time there is recurrence and midline crossing with root resorption.

## Clinical Significance

Multiple areas need to be evaluated to confirm that the tumor does not extend beyond the cyst wall, which is possible only after excisional biopsy. So diagnosis is often retrospective.

## References

- Reichart P A, Philipsen H P: Unicystic ameloblastoma. Odontogenic tumors and allied lesions. 1st Edn.; Quintessence Publication. Co. Ltd London, 2004; pp77-86.
- Ackermann G L, Altini M, Shear M: The unicystic ameloblastoma: A clinicopathologic study of 57cases. J Oral Pathol. 1988 ;17(9-10):541-546.
- L. R. Eversole, A. S. Leider, D. Strub, —Radiographic characteristics of cystogenic ameloblastoma, Oral Surg Oral Med Oral Pathol. 1984;57(5):572-7.
- T. J. Li, Y. T. Wu, S. F. Yu, G. Y. Yu, —Unicystic ameloblastoma: a clinicopathologic study of 33 Chinese patients, American Journal of Surgical Pathology 2000; 24(10) :1385–1392.
- R Wadhawan, Bhuvnesh S, Pulkit S, Dharti Gajjar. Unicystic ameloblastoma in a 23 year old male: A case Report. Int J Appl Dent Sci 2016;2(4):87-92.
- Hitesh S, Keerthilatha M P, Ankur K S, Monica C. Different Variants of Unicystic Ameloblastoma- A Report of Five Cases with CT Findings. OHDM. 2017; 16(2): 1-4.
- Reichart P A, Philipsen H P, Sonner S: Ameloblastoma: Biological profile of 3677 cases. Eur J Cancer B Oral Oncol. 1995; 31B(2): 86 - 99.
- Adekeye E O. Ameloblastoma of the jaws: A survey of 109 Nigerian patients. J Oral Surg. 1980; 38: 36-41.
- Robinson L, Martinez M G. Unicystic ameloblastoma: A prognostically distinct entity. Cancer 1977;40: 2278-85.
- Thankappan S, Thomas V, Kandamparambil S, Nair S. Unicystic ameloblastoma: 3 case reports and review of literature. J Indian Acad Oral Med Radiol 2008; 20:65-70.

### How to cite this article:

Lalit Gade, Sachin Kandalkar, Ketan Saraf, Mahesh Gadakh and Sachin Kandalkar. 2021. Unicystic Ameloblastoma Crossing Midline of Mandible : An Unusual Case Report. *Int.J.Curr.Res.Aca.Rev.* 9(05), 1-5. doi: <https://doi.org/10.20546/ijcrar.2021.905.001>